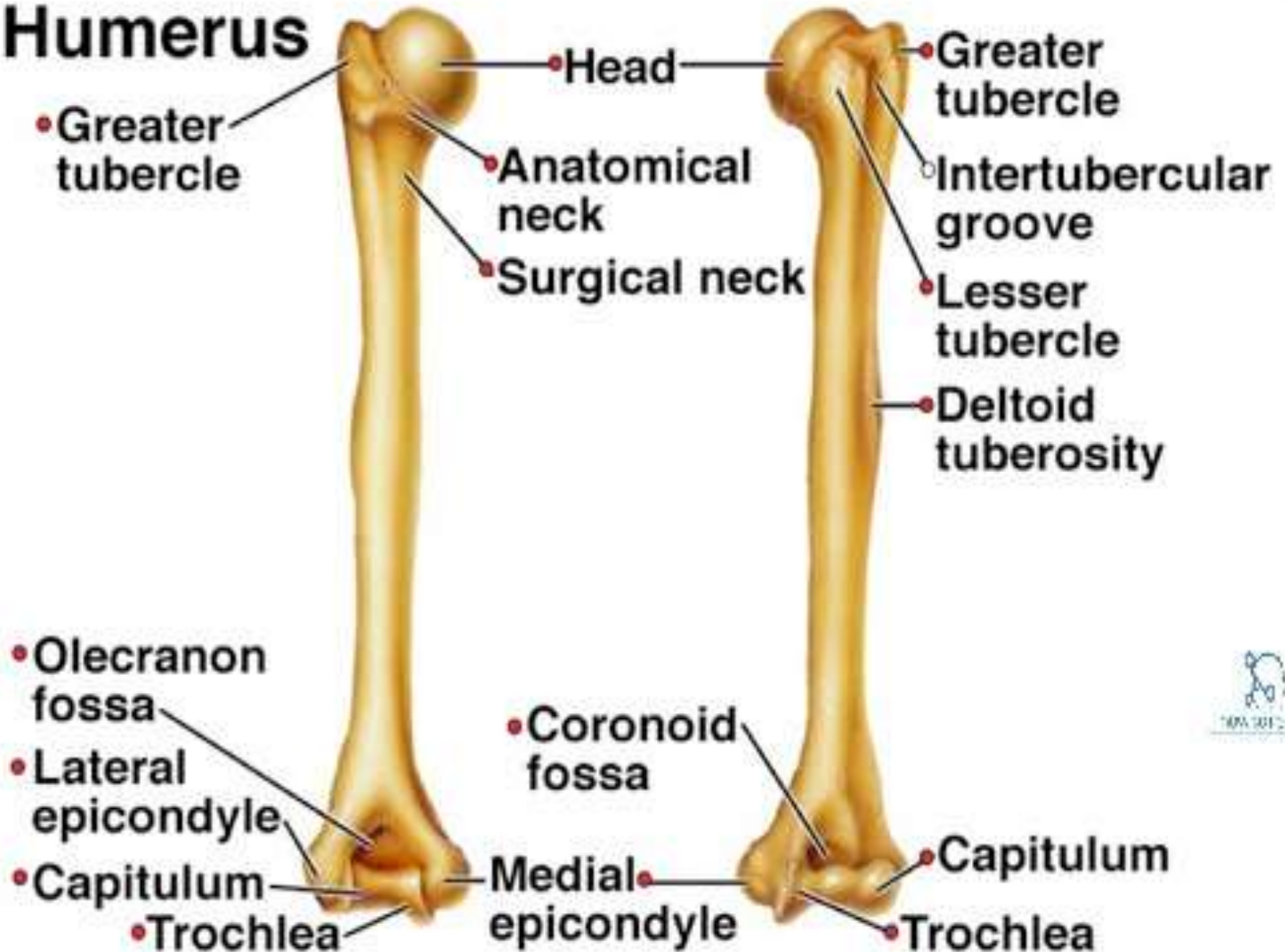


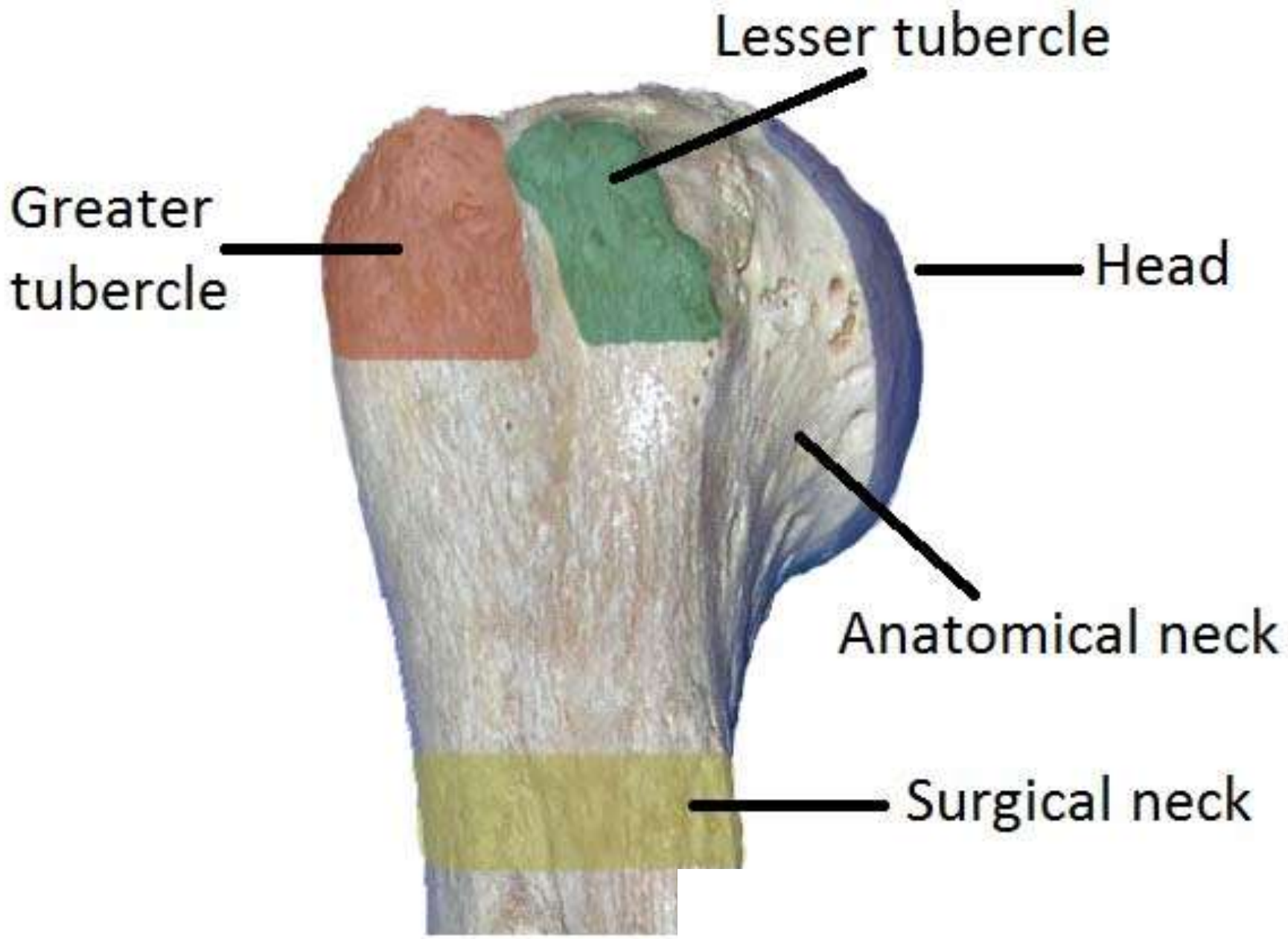
HUMERUS

**SARADA KRISHNA HOMEOPATHIC MEDICAL
COLLEGE & HOSPITAL**

**ANATOMY DEPARTMENT
GUIDED BY Dr. Zion Natharaj**

Humerus





Lesser tubercle

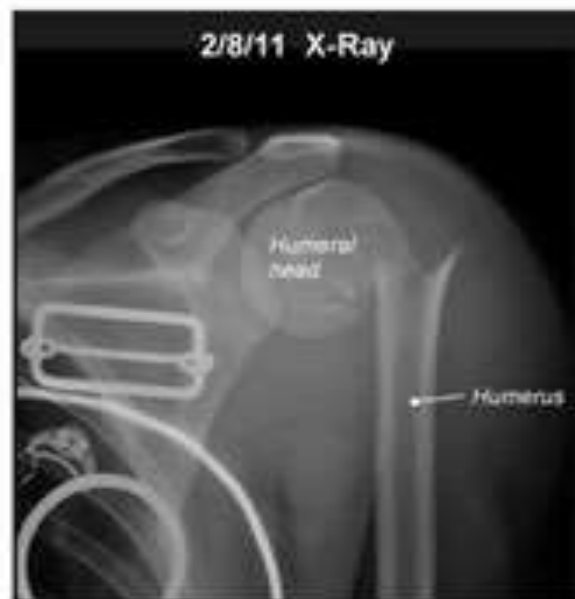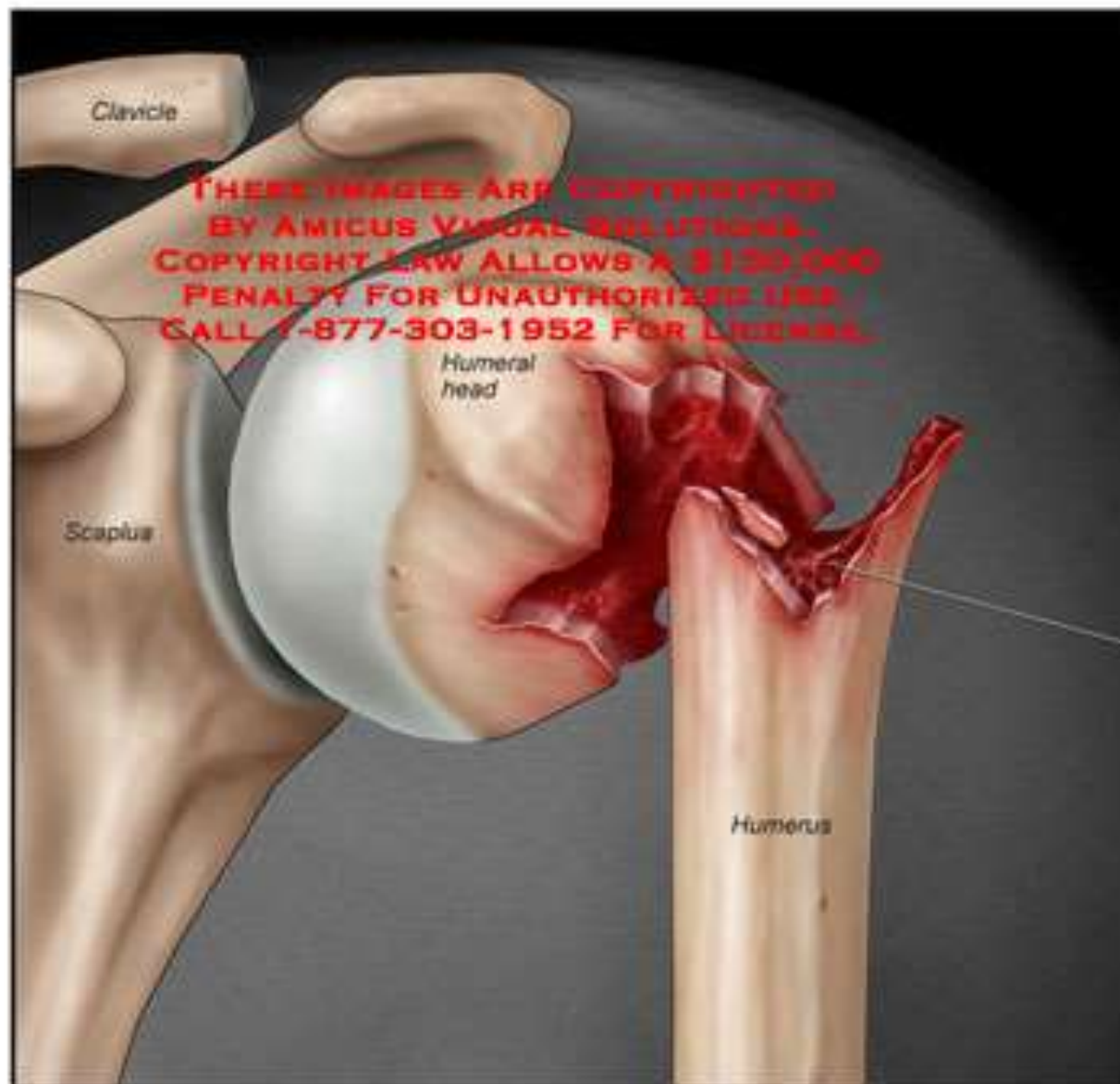
Greater tubercle

Head

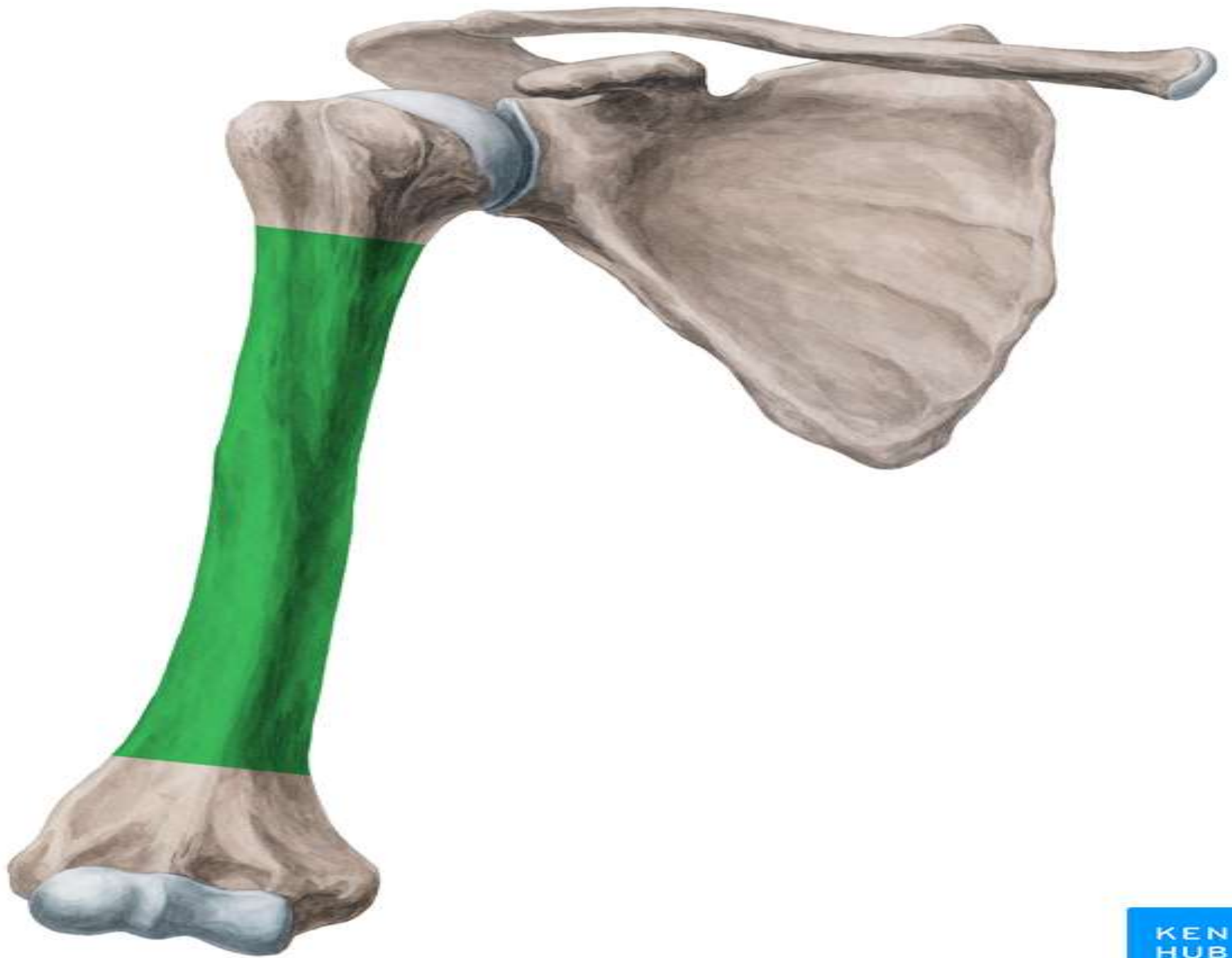
Anatomical neck

Surgical neck

's Left Humerus Fracture



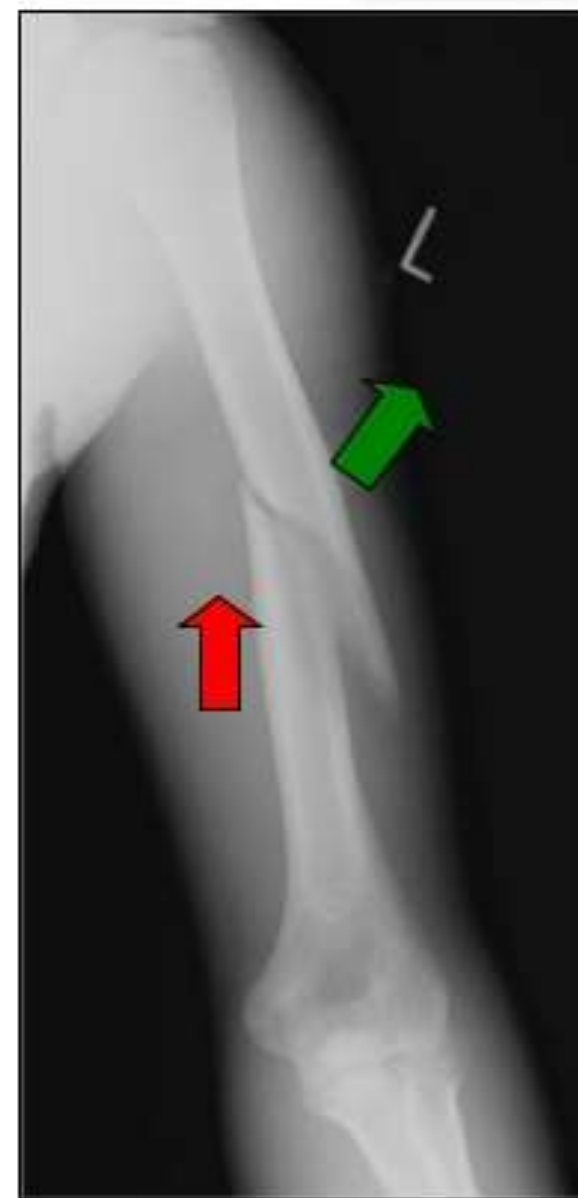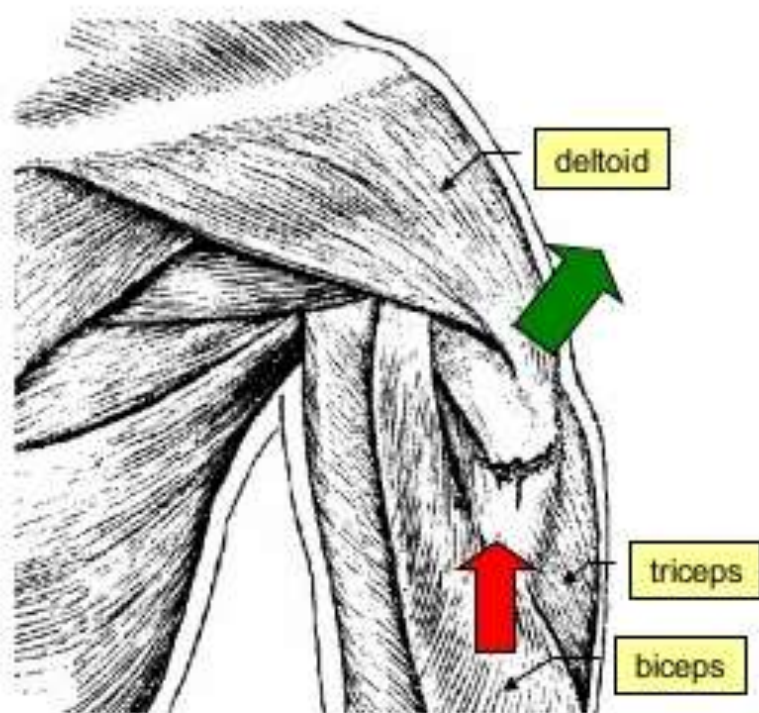
Comminuted fracture of left humeral metaphysis and surgical neck with approximately 90 degrees of angulation



Fracture of humeral shaft



- **Anatomy of displacement:** depends on the relation of the site of the fracture to the insertion of deltoid muscle
- When the fracture is distal to deltoid insertion
 - The proximal fragment is abducted by deltoid.
 - The distal fragment is pulled proximally by biceps and triceps.



Radial fossa

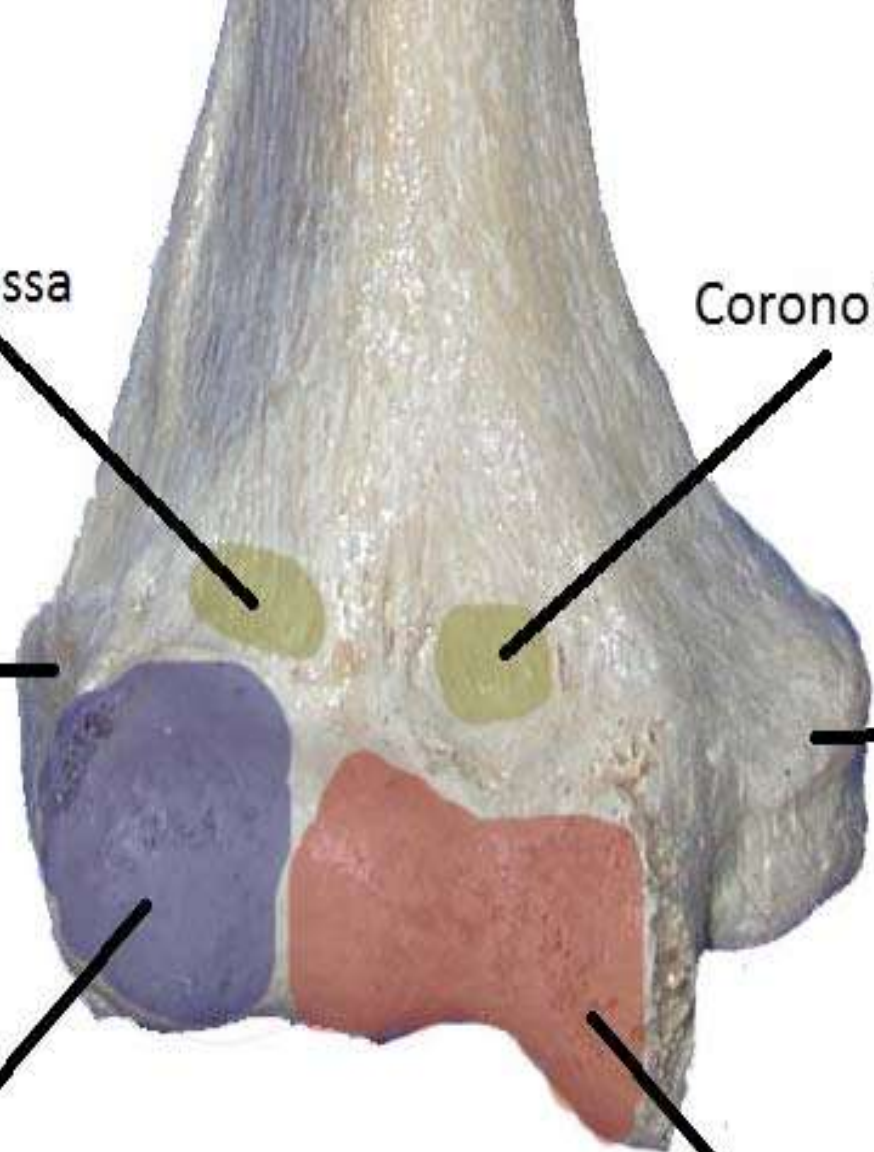
Coronoid fossa

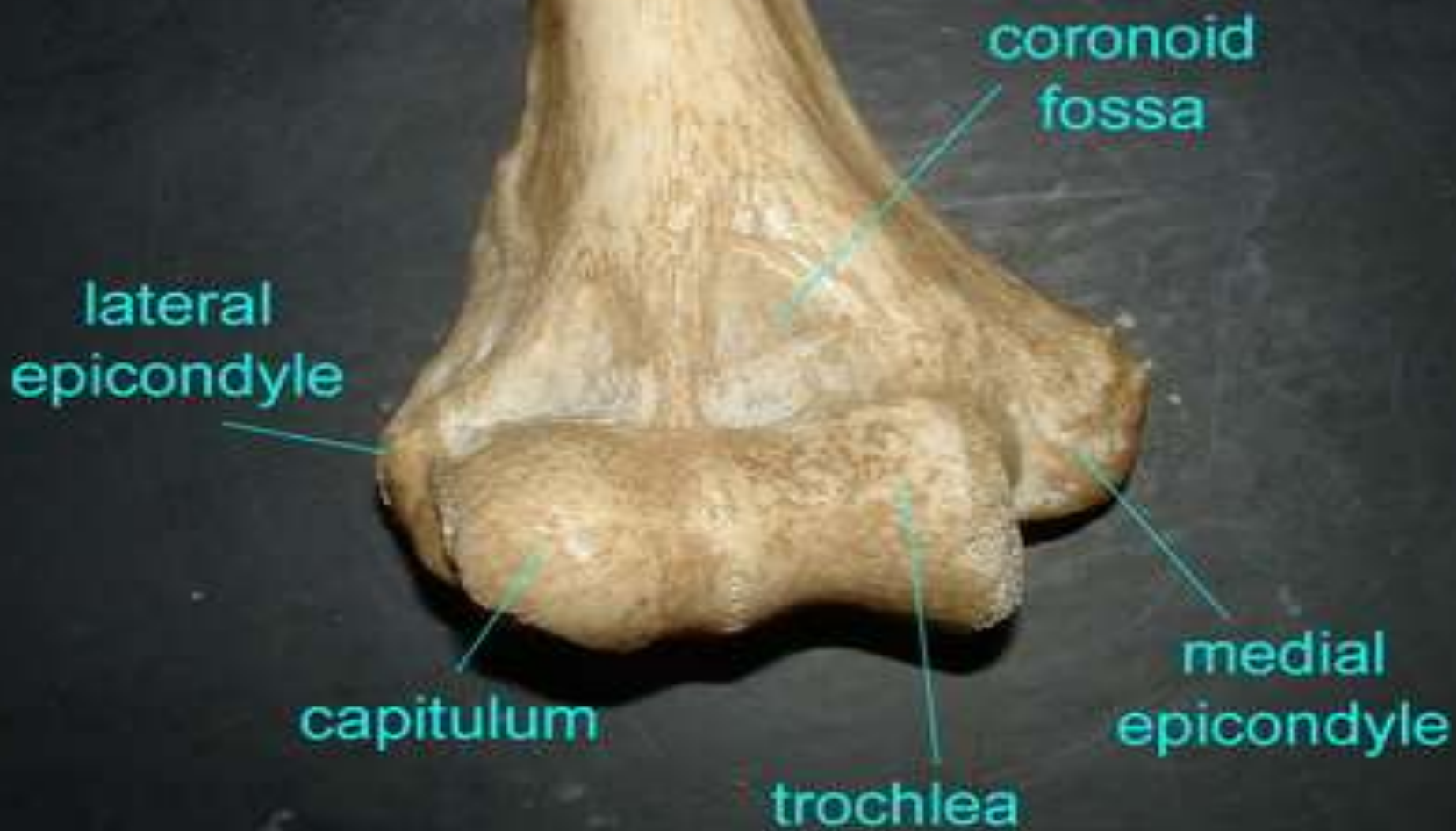Lateral
epicondyle

Medial
epicondyle

Capitulum

Trochlea

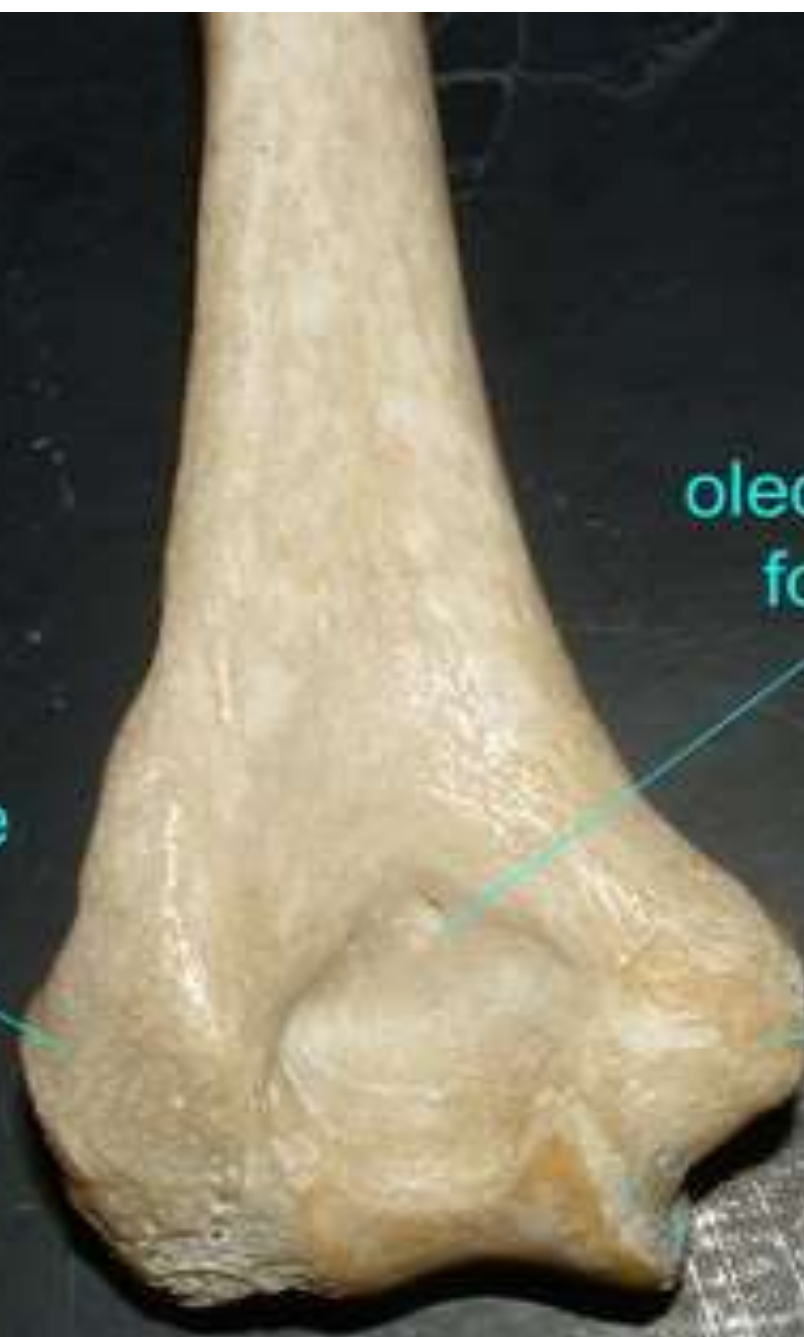


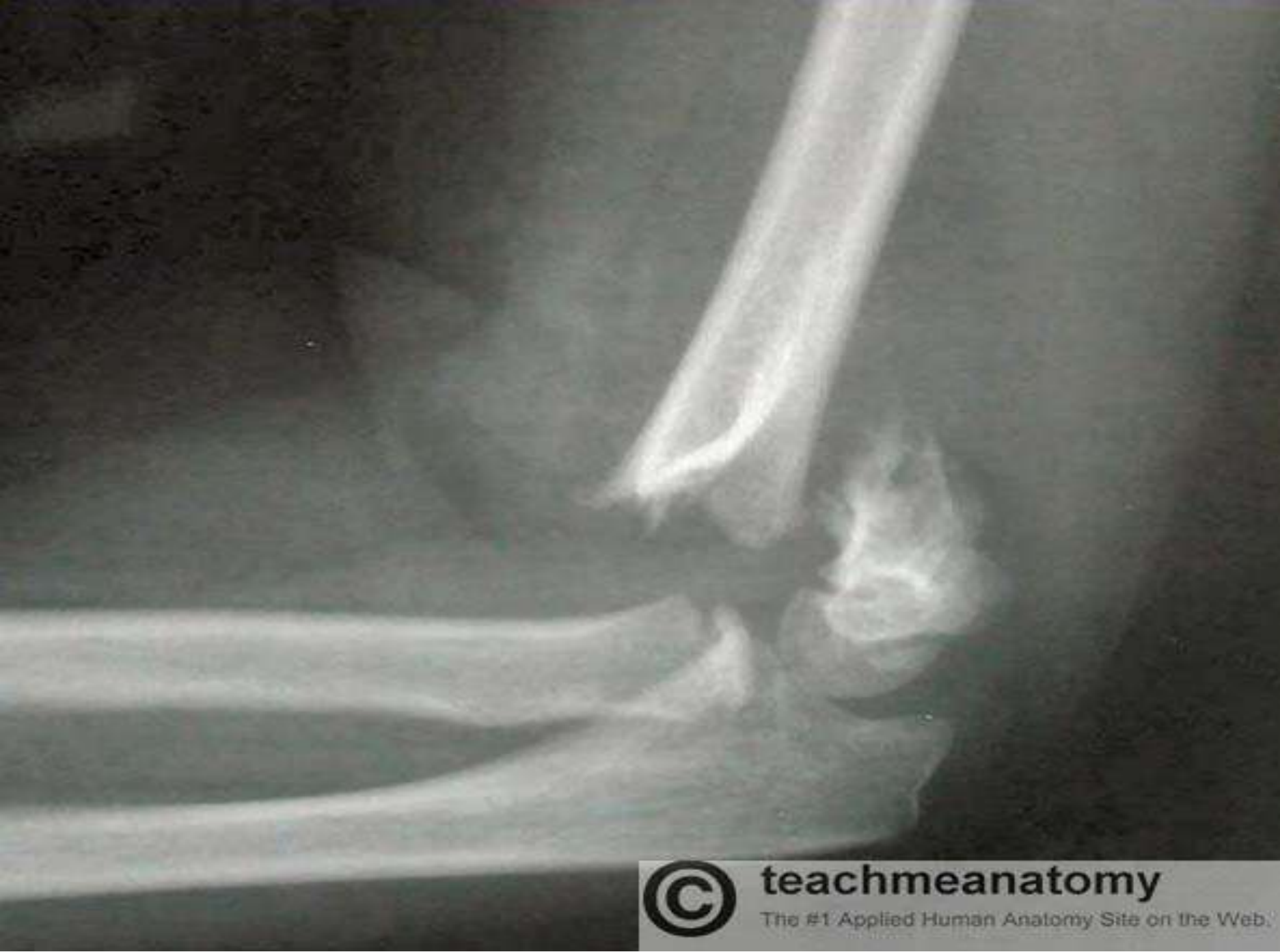
lateral
epicondyle

olecranon
fossa

medial
epicondyle



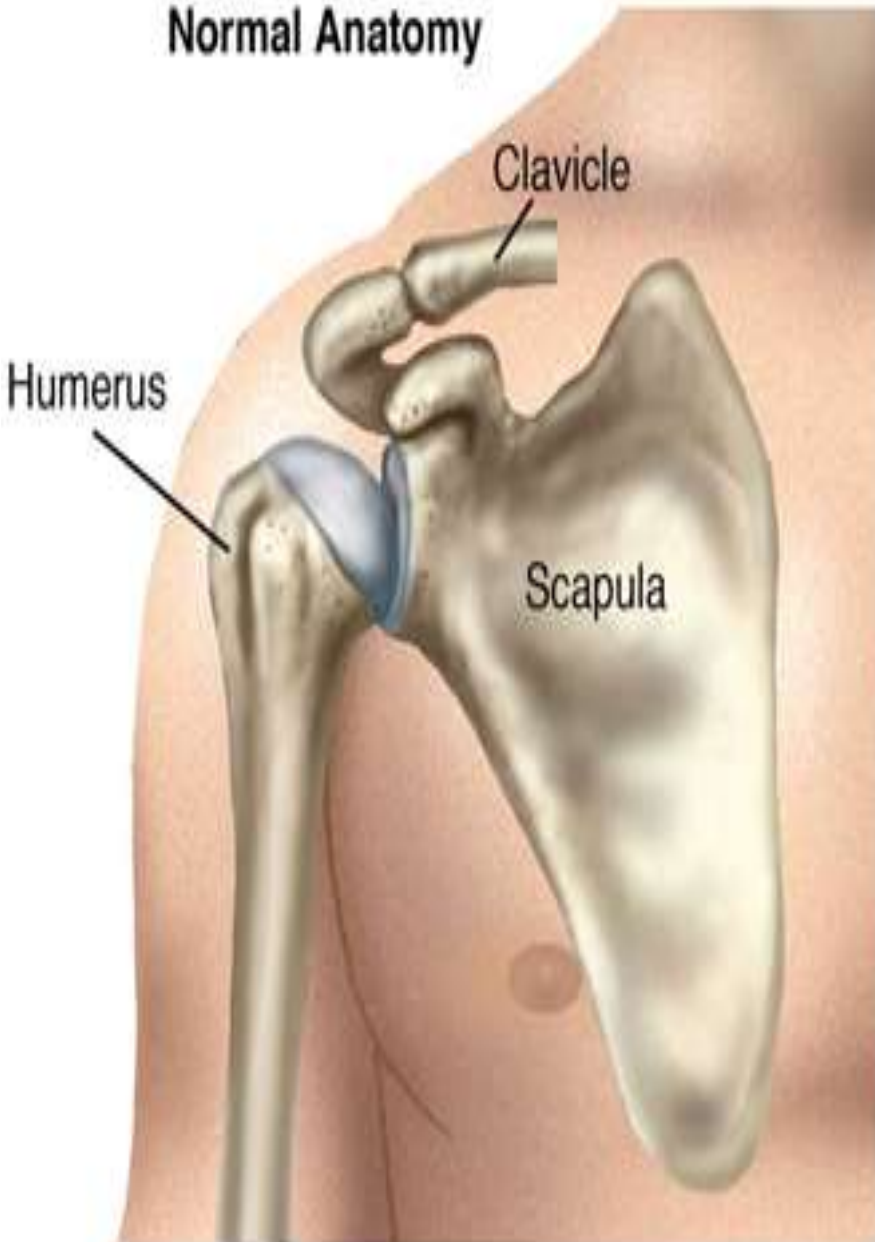


teachmeanatomy

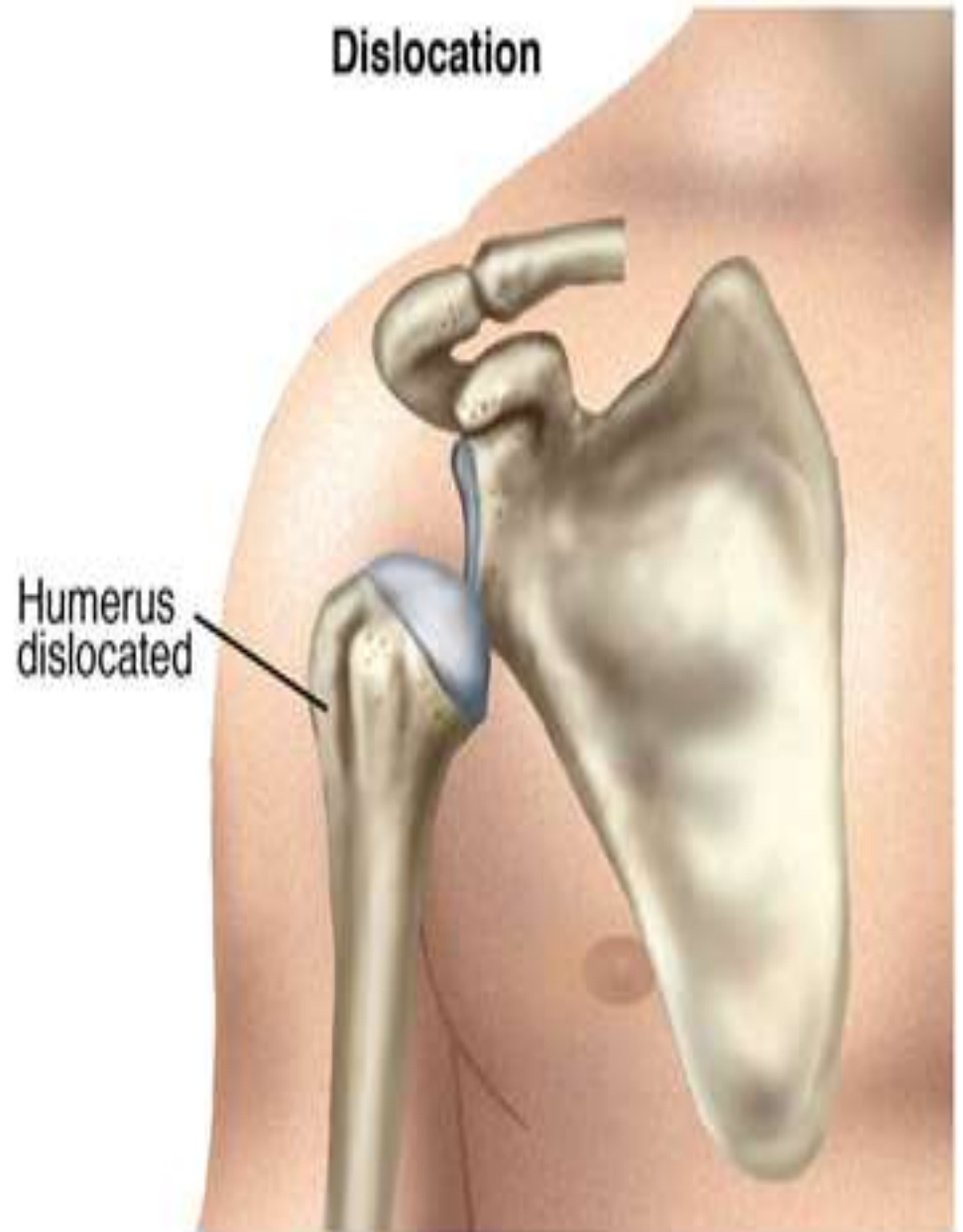The #1 Applied Human Anatomy Site on the Web.

Shoulder Dislocation

Normal Anatomy



Dislocation



THANK YOU